

A RADIOLOGY WORKSTATION FOR MAMMOGRAPHY: PRELIMINARY OBSERVATIONS, EYETRACKER STUDIES, AND DESIGN

Beard DV, Johnston RE, Pisano, E, Hemminger, B, and Pizer, SM
Department of Radiology
University of North Carolina at Chapel Hill

ABSTRACT

For the last four years, the UNC FilmPlane project has focused on constructing a radiology workstation facilitating CT interpretations equivalent to those with film and viewbox. Interpretation of multiple CT studies was originally chosen because handling such large numbers of images was considered to be one of the most difficult tasks that could be performed with a workstation. We are now extending the FilmPlane design to address mammography. The high resolution and contrast demands coupled with the number of images often cross-compared make mammography a difficult challenge for the workstation designer.

This paper presents the results of our preliminary work with workstation interpretation of mammography. First, we present background material to justify why we believe electronic mammographic workstations could improve health care delivery. Second, we describe the results of several observation sessions and a preliminary eyetracker study of multiple-study mammography interpretations. Finally, we present our tentative conclusions of what a mammographic workstation might look like and how it would meet clinical demand to be effective.

1. BACKGROUND

Screening mammography has proven to be an effective procedure in identifying early breast cancer. Through two randomized trials, breast cancer mortality among screened women over 50 years old has been reduced at least 30% when compared with unscreened controls. [Shapiro, 1982; Tabar, 1989; Shapiro, 1988]. The cancers found by mammography tend to be smaller and of less advanced stages than those found by breast physical examination or breast self-examination. [Baker, 1982; Saltzstein, 1984; Fletcher, 1984]. Smaller and lower stage breast cancers have better five, ten and twenty year survival rates. [Fisher, 1969; Wanebo, 1974; Gallager, 1971; Frazier, 1977].

Unfortunately, approximately 10% of clinically obvious breast cancers are not visible with mammography. [Baker, 1982] This occurs most frequently in patients with large amounts of breast glandular tissue. [Baker, 1982; Stomper, 1989]. The density of this tissue tends to obscure underlying pathology. Premenopausal women and women undergoing estrogen replacement therapy are more likely to have dense glandular breasts. This may partially explain why randomized trials have failed to demonstrate a significant reduction in breast cancer mortality for women under 50 years old. [Shapiro, 1986]. Furthermore, tumor doubling times are shorter in younger women [Moskowitz, 1986]. With current technology, for women under 50, the average interval between mammographically-apparent disease and clinically apparent disease averages only 1.5 to 2 years. For women over 50, this interval averages 3.5 to 4 years [Moskowitz, 1986]. The American College of Radiology (ACR) and the American Cancer Society (ACS), among other organizations, currently advocate screening mammography for women between 40 and 49 years old every one to two years. Therefore, it is desirable to increase the sensitivity of mammography in these patients so that their cancers are apparent the first time they are present. This earlier detection may result in significantly reduced mortality in this population.

Mammographic technology has improved dramatically in the last two decades. These improvements include the development of dedicated mammography equipment with appropriate x-ray beam quality, grid capability, adequate breast compression and automatic exposure control. In addition, magnifica-

tion techniques with very small focal spot size have become widely available. Better film-screen systems and appropriate film processing have also been developed to improve film contrast [Kimme-Smith, 1990; Haus, 1990]. Over the same time period, the average glandular radiation dose from mammography has dropped, generally because of the development of faster film-screen combinations. [Feig, 1990].

Along with the improvement in the hardware for acquiring mammographic image data, it is also critical that appropriately trained technologists use the equipment and that radiologists trained in the specialty of mammography interpret the images in order to achieve the best sensitivity and specificity for early cancer detection. If there existed a viable electronic workstation, then it would be feasible to send the mammography image to the highly trained radiology specialist who is not usually located at the various screening sites in clinics, mobile vans, etc.

In addition an electronic workstation could provide access to contrast enhancement techniques that optimize the greyscale assignment for the display of mammograms, possibly bringing out abnormalities that otherwise might not have been seen, or possibly save the patient from returning for additional studies.

It is clear that an electronic mammographic workstation is a potentially valuable asset in the growing field of screening mammography by providing remote access of images to the expert mammographer, and by providing image processing capability that could improve earlier detection of breast cancer. These advantages can only be realized if the workstation can provide adequate spatial resolution and fast response times.

Grey level assignment of recorded image intensities is an unavoidable step of the electronic display of medical images. One critical advantage of a workstation over film is dynamic grey-level assignment, that is, the ability to change dynamically the grey-level window width and level (WWL) used to display an image [Judy 1982, Judy 1985, Seeley 1987]. The choice of windowing tool is critical, both for reducing total interpretation time and avoiding beginning-user confusion. An intensity windowing tool should correspond to a user's mental model of the windowing operation [Walker J. 1990].

While radiologists need the ability to access all possible intensity windows, most often a selection from a small standard set of WWLs refined for CT images of bone, lung, soft tissue, brain, etc. is sufficient. With a workstation, the radiologist can rapidly change the contrast range of a displayed image.

Algorithmic grey-level assignment intended to show contrasts over a wide range of recorded intensities, such as contrast-limited adaptive histogram equalization (CLAHE) and unsharp masking (USM), are also useful because, ideally, they reduce the need for manual contrast-adjustment (improving workstation interaction) and may improve interpretation quality. These methods allow the radiologist to simultaneously view all the intensity information contained in the image. Overviews of contrast enhancement may be found in [Pizer 1987b] and [ACR 1986]. Discussion of detailed topics also can be found in [Hori 1988, Pizer 1987a, Zimmerman 1987, Zimmerman 1988].

We have carried out pilot studies where we applied CLAHE to digitized images of the ACR mammography phantom. The images were digitized at 0.1 mm per pixel. This phantom simulates a 4.5 cm thick compressed breast consisting of 50% glandular tissue and 50% adipose tissue. It contains simulated fibers, microcalcifications and masses ranging in size from those easily seen to those unseen on standard mammographic films. A qualitative assessment of images of the test phantom that have been digitized and contrast enhanced show about the same amount of detail as do the original film images. By optimizing the CLAHE parameters we are encouraged to believe that even greater improvements in the image might be possible.

We have also looked at a number of mammograms digitized at 100 microns per pixel. In some cases, structures that were not remarkable on the original film appeared suspicious on the enhanced image. For example, a cancer that appeared as an unremarkable mammographic density on the original images was demonstrated with these techniques to be in fact a spiculated mass, an obvious mammo-

graphic marker of malignancy. It could be that where the abnormality is subtle and below the threshold that would draw the attention of most, if not all, radiologists reading the mammogram, application of a contrast enhancement technique could bring the abnormality above the attention threshold. These preliminary studies demonstrate the potential value of having mammograms in digital format and displayed on interactive electronic workstations.

2. OBSERVATION OF MAMMOGRAPHY INTERPRETATION

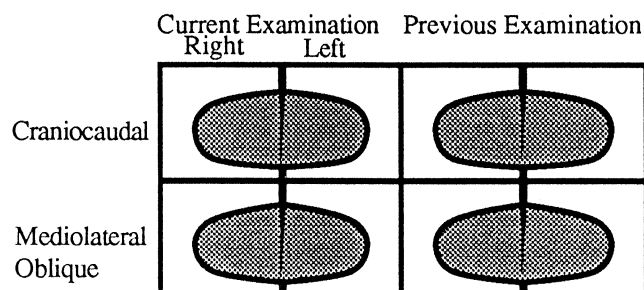


Figure 1
One Viewbox Organization for Mamographic Images

Recently we have conducted observation sessions of three mammographers interpreting multiple mammography screening examinations. While objectives and image handling procedures were similar to those for CT interpretation [Beard 1990a], there were several significant differences. The mammographers all loaded the four images from each exam onto the viewboxes and either covered all remaining viewbox space to minimize glare, or used special viewboxes designed specifically for mammography. As with other interpretations, the radiologists seemed to view the images as they were being loaded. Films were loaded using a two-over-two grid arrangement with the left and right images in columns, the craniocaudal images on top row and the mediolateral-oblique on the bottom row (Figure 1). Each image was examined individually, sometimes with a magnifying glass, and then the images were side-by-side compared to either the corresponding image from the other side, the other view of the same breast, or an image from a previous study. One radiologist would slightly move an image up or down on the viewbox to horizontally align anatomy from the right and left images to facilitate side-by-side comparison. The radiologists also rotated and translated images allowing "mirror image" comparison of anatomically-aligned image pairs including right/left, current/previous, and craniocaudal/mediolateral-oblique (Figure 2). After examination of the images and any related documentation, the radiologist would interpret a report or fill in an interpretation form. Subsequent action would include scheduling the patient for a magnification view, or recommending a repeat exam or a biopsy.

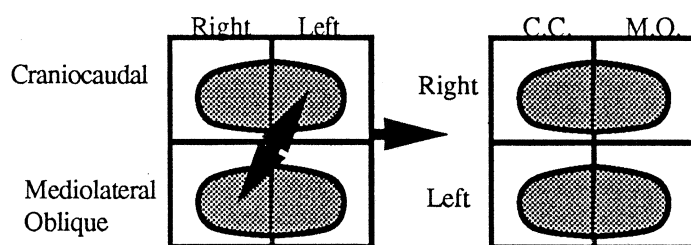


Figure 2
Alternative arrangement allowing CC/MO comparisons

These results indicate that radiologists have the following needs for interpretation of mammography examinations: 1) rapid comprehension of the images in the patient folder and their relationships; 2) rapid arbitrary or sequential access to images; 3) rapid side-by-side comparison of images from different studies; 4) rapid image rotation and alignment.

In addition to the observation sessions, we used an eyetracking device (Mark IV Eyetracker) that tracks the eye movement as the radiologist views the radiographic films. This allows us to obtain quantitative data as to where the radiologist is actually looking and track rapid eye excursions as she scans through the mammographic study. The eye tracker allows the mammographer full freedom of head and body motion and doesn't interfere with the normal reading process.

We used four randomly selected cases from the clinic. All four cases had previous studies and three cases had magnification views. Thus, each study consisted of from 8 to 12 images. The radiologist with special expertise in mammography was presented a folder containing the films and asked to read and dictate a report. We used a four over four viewbox. The radiologist loaded the films on the viewbox such that the most recent study was loaded horizontally on the lower four panels. One pattern used was to place the right mediolateral oblique image adjacent to the left mediolateral oblique, and the right craniocaudal adjacent to the left craniocaudal image. The previous case was loaded on the upper panels in the same order so that the old right mediolateral oblique was directly above the new right mediolateral oblique, etc. Some radiologists prefer to order the older study on the right hand viewboxes and the most recent study on the left hand viewboxes. In either order, the right and left breast image for a given view, was located in mirror image and adjacent to each other (see Figure 1). The mammographer quickly visually scanned each separate image and then rapidly compared the right to left breast images of a given view. Then comparisons were made between a given view of the recent image of the right breast and the same view of the same breast image from the older study. This pairwise comparison was made for each view, first between right and left of the most recent study, then between the old and new study of that breast and view. Scan time for viewing three or more pairs of images was under 6 seconds.

If there were magnification images, these were also consulted and compared to the non-magnification image of the same breast and view. In this case the film located next to the image to be compared was removed and replaced by the magnified image. General viewing of the complete breast was done with the eyes located at about 18 inches from the viewbox. Closer inspection, often with a magnifying glass to achieve better spatial resolution, was done at about 6 to 8 inches. The whole process of viewing of a patient study often took less than a minute to accomplish. The close scrutiny of selected subregions was done in a second or two.

What this implies to the workstation designer is that it appears important to simultaneously display all images in the study in order to have rapid access to each image in the patient study, and to be able to rapidly rearrange the ordering of images for side by side comparisons. If one were to display simultaneously a study set of 8 images at 50 microns resolution, one would need a screen space of 10.4 k x 8 k pixels. However, our pilot study implies that for the display of the complete set of images, where the radiologist is doing an initial scan of the mammogram study, they may not have to be at maximum resolution, but may be as poor as 200 microns. One might get away with this if the response time to call up a higher resolution image is rapid enough, say a second or less, and the user interface minimizes manual selection and manipulation of images.

3. MAMMOGRAPHY WORKSTATION DESIGN

The purpose of a radiology workstation is to facilitate effective and efficient electronic interpretation of medical images. Given the other cost and logistic advantages of a Picture Archive and Communication System (PACS) [e.g., Beard 1990b, Arenson 1990], a viable radiology workstation must facilitate interpretation reports of the same or better quality as those from film and viewbox, and in the same or less time. The quality of the images displayed on the workstation's monitors is critical [see, Pizer 1985, Arenson 1990, MacMahon 1986, Chakraborty 1986, Goodman 1986], but this is only part of the problem. A poorly-designed computer human interaction (CHI) – the workstation's ability to navigate through the images in the patient folder – can obviously increase the total time for

the interpretation. But worse, a confusing, slow CHI can degrade the quality of the interpretation report [Foley 1990].

Radiologists must comprehend the images through which they navigate. An image index allows them to understand the images in the patient folder, including their modalities, extents, and temporal and anatomical locations. Such an image index provides a *mental model* of the workstation operation to the radiologist [Rumelhart 1981, Young 1981, Foss 1982, Halasz 1982, Douglas 1983, Dumas 1985, Olson 1987]. It augments working-memory during the cognitively-demanding interpretation task. A number of image indexes have been proposed. The original Arizona workstation [McNeill 1987] used a text listing of all examinations in the patient folder and the all images in each examination. An icon index has also been proposed [Rogers 1989] in which a simple stick-figure icon of a body is used to represent and access the contents of the patient folder.

At UNC we have developed a prototype workstation the we have coined *FilmPlane*. The operation of our FilmPlane system is based on the metaphor of a two-dimensional *navigation view* or pictorial image-index upon which all the images in the patient folder are systematically arrayed in two, four, or more column strips (Figure 1) [Beard 1990a&c]. Navigation views exploit the fact that miniature images can serve as image icons to radiologists with highly-developed image-recognition skills.

A radiology workstation to be used for the primary interpretation of multiple studies, must be carefully designed to overcome two critical limitations: the lack of enough display area (in pixels) to show a sufficient number of sufficiently large images, and the lack of dynamic grey-scale range, causing difficulty in displaying the full recorded data for each pixel.

From the literature (Oestmann, 1988, Chan, 1987) it is reported that detection of microcalcifications requires at least 100 microns/pixel resolution and probably 50 microns. For mammographic films that are 19 cm by 24 cm, at 100 microns/pixel, this means a matrix size of 1900 x 2400. We have found that we can crop this to about 1000 x 1800 and still retain the complete breast image. We would assume that digitization at 50 microns is necessary which means each image requires 2000 x 3600 pixels by 16bits, or 14.4 megabytes. A single patient study with four images would be 57.6 megabytes, and in cases where there is a previous study and one or two magnification views, we are up to a memory size of about 175 megabytes. In order to achieve fast enough response to display various arrangements of the mammograms for comparisons, the most likely arrangements must be precomputed and stored. This, of course, increases the memory size even further.

A viable mammography workstation design also must allow rapid comprehension of patient folder contents, side-by-side comparison of left/right craniocaudal/ mediolateral-oblique and previous/current images; alignment of symmetric anatomy, random and sequential image access, and dynamic and preset contrast adjustment.

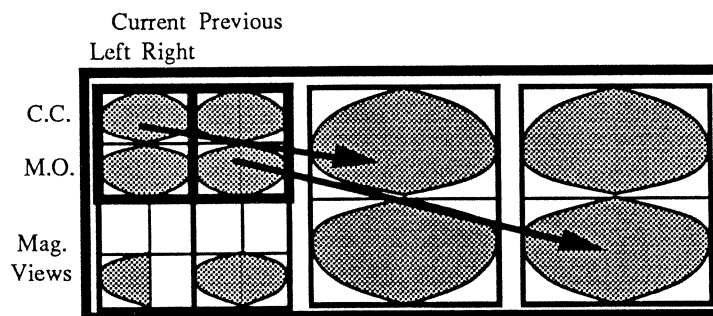


Figure 3
Three Screen Mammography Workstation:
100µm comparison of Current and Previous Study.

Our prototype workstation, FilmPlane, is a research tool which we have used as a CT workstation [Beard 1990]. We are in the process of modifying the software to operate with three 2K² displays. While the initial software port is straightforward, considerable time and programming effort is required to reduce the response time of critical operations (e.g., scroll) to acceptable levels. Even when cropped to the edges of the breast, some mammograms digitized to 50 microns/pixel will be larger than the 2K² monitors necessitating both continuous and discrete roaming, as well as discrete zooming.

Figure 3 shows one possible variation of a navigation view for mammography. The four images from a typical study are stored in a 4X4 grid with left and right images in their respective columns, cranio-caudal images in the top row, and mediolateral-oblique images in the bottom. Symmetric images are views, or other special views, could be located below their respective studies. By varying the size of the viewport, 100 micron to 50 micron, images can be viewed and compared (Figure 4 and 5).

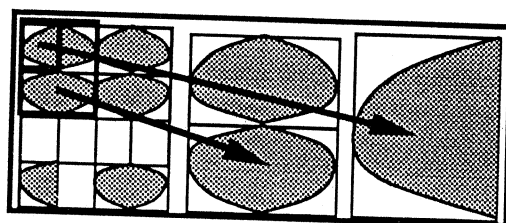


Figure 4
50 μ m and 100 μ m comparison of
current examination.

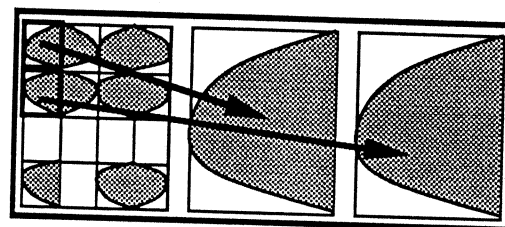


Figure 5
50 μ m comp. of current right CC &
MO. Images can be rotated.

4. CONCLUSIONS

One of the most demanding uses of an electronic workstation is for the display of mammographic images. Mammograms are high resolution images, digitized at 50 microns/pixel, consist of complex structures with very little difference in tissue density which results in low contrast. Interpretation requires rapid comparison among several images, 2 or more, and rapid access to 8 to 12 images.

Our observer and eyetracking studies of radiologists reading mammographic studies on multipanel viewboxes, show that the radiologist needs to have a rapid comprehension of the images in the patient folder, rapid arbitrary or sequential access to the images, rapid side-by-side comparison of images from different studies or within a study, and the ability to realize the maximum resolution available for the image. This dictates that the workstation must have adequate screen space (matrix size) to display one or more images at the highest resolution and all the images at intermediate resolution. The user must be able to arrange the images for comparison of right to left, or old to new, as rapidly as they would handling films on the viewbox. To meet these demands, the workstation must have on the order of 200 megabytes of memory, and interaction of the user and the displayed images must be real-time.

We propose a prototype workstation that could be used to test these concepts. If successful, then all the advantages of digital image processing, transfer and storage are available to mammography. If a mammographic workstation is viable, we suggest that it should also be a viable workstation for a broad range of radiographic image presentations.

4. REFERENCES

- ACR *Engineering Research in Visual Perception*. A publication by the American College of Radiology, 1986.
- Arenson RL, Chakraborty DP, Seshadri SB, Kundel HL, The Digital Imaging Workstation, *Radiology* 1990, 176:303-315
- Baker LH: "Breast Cancer Detection Demonstration Project: Five-Year Summary Report", *CA* 32(4), 194-225, 1982.
- Beard, DV and Walker, JQ, Navigation Techniques to Improve the Display of Large Two Dimensional Spaces. Accepted by *The Journal of Behaviour & Information Technology*, 1990
- Beard, DV, Parrish, D, Stevenson, D, A Cost Analysis of Film Image Management and Four PACS systems based on Four Network Protocols, *the Journal of Digital Imaging*, May 1990.
- Beard DV, Designing a Radiology Workstation: Focus on Navigation During the Interpretation Task, *Journal of Digital Imaging* Aug 1990.
- Chakraborty DP, Breatnach ES, et al., "Digital and Conventional Chest Imaging: A Modified ROC Study of Observer Performance Using Simulated Nodules," *Radiology*, Jan. vol. 158, pp. 35-39, 1986.
- Chan HP, Vyborny CJ, MacMahon H, Metz CE, Doi K, and Sickles EA: "Digital Mammography ROC Studies of the Effects of Pixel Size and Unsharp-Mask Filtering on the Detection of Subtle Microcalcifications", *Invest Radiol* 22: 581-589, 1987a.
- Douglas SK and Moran, TP "Learning text editor semantics by analogy," *Proceedings of the CHI'83 Conference on Human Factors in Computing Systems*, 1983.
- Dumas ST and Jones WP, "A comparison of symbolic and spatial filing," *Proceedings of the CHI '85 Conference on Human Factors in Computing Systems*, ACM, 127-130, 1985.
- Fisher B et al.: "Cancer of the breast: Size of neoplasm and prognosis", *Cancer* 24, 1071, 1969.
- Fletcher SW, O'Malley MS, Bunce LA: "Physicians abilities to detect lumps in silicone breast models", *JAMA* 251, 1580, 1984.
- Foley WD, Jacobson, DR, Taylor AJ, et. al, Display of CT Studies on a Two-Screen Electronic Workstation Versus a Film Panel Alternator: Sensitivity and Efficiency Among Radiologists, *Radiology*, 174, 769-773, March 1990.
- Foss D, Rosson M, and Smith P, "Reducing manual labor: An experimental analysis of learning aids for a text editor," *Proceedings of the Gaithersburg Conference on Human Factors in Computing Systems* (Washington, DC: National Bureau of Standards), pp 332-336, 1982.
- Frazier TG, Copeland EM, Gallager HS et al., "Prognosis and treatment in minimal breast cancer", *Am. J. Surg* 133, 697, 1977.
- Gallager HS, Martin JE: "An orientation to the concept of minimal breast cancer", *Cancer* 28: 1505, 1971.
- Goodman LR, Foley WD, et al., Digital And Conventional Chest Images: Observer Performance with Film Digital Radiography System," *Radiology*, Jan. 158 27-38, 1986.
- Halasz F and Moran TP, "Analogy considered harmful," *Proceedings of the Gaithersburg Conference on Human Factors in Computing Systems* (Washington, DC: National Bureau of Standards), 1982.
- Haus AG: "Technologic Improvements in Screen-Film Mammography", *Radiology* 174(3), 628-637, 1990.
- Horii S, Horii H, and Kowalski P, "Eclectic Look at Viewing Station Design," *SPIE Medical Imaging II*, Newport Beach CA., 914, 920-928, 1988.
- Judy PF, and Swensson RG, "Detection of Small Focal Lesions in CT Images: Effects of Reconstruction Filters and Visual Display Windows ", *Brit. J. Radiology* 58: 137-145, 1985.
- Judy PF, Swensson RG, Twible D, and Menelly L, "Effects of Display Level on Detectability of Small Lesions on CT Images," *Medical Physics* 10 (4): 525, 1982.
- Kimme-Smith C, Bassett LW, Gold RH, Zheutlin J, Grombein JA: "New Mammography Screen/Film Combinations: Imaging Characteristics and Radiation Dose", *AJR* 154, 713-719, 1990.